

The optimum duration of anterior nasal packing after common nasal surgeries

Ahmed M. Abdelghany, Ashraf S. Elhamshary, Elsayed A. Hegazy, Abd E. F. Ghallab

Department of Otorhinolaryngology, Faculty of Medicine, Benha University, Benha, Egypt

Correspondence to Elsayed A. Hegazy, M.B.B.CH, Department of Otorhinolaryngology, Faculty of Medicine, Benha University, Bera Elagoz, Quesna, Menufia 12345, Egypt
Tel: +20 109 570 5703; 01095705703
e-mail: zeko_hegazy@yahoo.com

Received 25 December 2019

Revised 06 January 2020

Accepted 13 January 2020

Published 21 January 2021

Pan Arab Journal of Rhinology
2020, 10:84–88

Background

Anterior nasal packing (ANP) after nasal surgeries usually causes significant pain and discomfort. Up to the best of our knowledge, there is no evidence accepted for the optimum duration of postoperative ANP.

Objective

The aim was to determine the optimum duration for ANP in patients undergoing common nasal surgeries associated with the least discomfort and complications.

Patients and methods

A prospective randomized clinical study was carried out in Benha University Hospital from November 2018 to August 2019. It included 150 patients who underwent common nasal surgeries: submucosal resection of the nasal septum and/or inferior turbinoplasty or functional endoscopic sinus surgery. Patients were allocated into four groups (A, B, C, and D) according to the duration of ANP (6, 12, 24, and 48 h, respectively). The groups were compared regarding pain during removal of the pack, epiphora, dysphagia, sleep disturbances, bleeding, infection, septal hematoma, septal perforation, crustations, and adhesions.

Results

Mean pain score was significantly lower in group A and higher in group D. Incidence of epiphora and sleep disturbances before pack removal was significantly lower in group A and higher in group D regardless of the type of surgery, whereas it was not significant regarding dysphagia. Bleeding, infections, crustations, hematoma, adhesions, and septal perforations showed nonsignificant statistical difference among the four groups.

Conclusion

Early removal of ANP is significantly associated with better patient comfort and less pain and does not increase the incidence of other complications.

Keywords:

anterior nasal pack, duration, nasal surgery, optimum

Pan Arab J Rhinol 10:84–88
© 2021 2090-7640

Introduction

Nasal operations are variable and numerous. They vary from simple procedures to very complicated operations. Complications after nasal surgeries include excessive bleeding; wound infection; septal hematoma; abscess; perforation; saddle nose deformity; nasal tip depression; sensory changes, such as anosmia or dental anesthesia; cerebrospinal fluid rhinorrhea; and others [1,2].

Anterior nasal packing (ANP) has been used as a traditional step after nasal surgeries, aiming to prevent bleeding and hematoma and stabilize internal or external nasal components. There is no universally accepted time to remove ANPs, and this time varies among surgeons and hospitals from few hours to 48 h or more [3]. Nasal packing removal is the worst step, annoying most of the patients and may be considered as their nightmare.

However, there is no scientific evidence to support its benefit, and ANP may become an inconsequential procedure. It leads to discomfort/pain (especially upon removal), bleeding during its removal, vagal reflex, nasal mucosa trauma, epiphora, local infection, discomfort in swallowing, sleep disturbances, displacement with aspiration, and rarely, toxic shock [4]. These circumstances led us to search for the best time to remove the nasal pack.

Aim

The aim was to determine the optimum duration of ANP in patients undergoing common nasal surgeries.

This is an open access journal, and articles are distributed under the terms of the Creative Commons Attribution-NonCommercial-ShareAlike 4.0 License, which allows others to remix, tweak, and build upon the work non-commercially, as long as appropriate credit is given and the new creations are licensed under the identical terms.

Patients and methods

A prospective randomized clinical study done on 150 patients attending Benha University Hospital outpatient clinics from October 2018 to August 2019. The patients had significantly deviated nasal septum and/or hypertrophied inferior turbinates or chronic sinusitis and were indicated for surgery according to their diseases.

Patients older than 50 years or younger than 18 years were not included in the study. In addition, patients with history of nasal surgery, severe uncontrolled systemic illness such as coagulopathies, immunodeficiency, renal failure, or tumors were not included.

All operative and nonoperative procedures were explained in full details to the patients, who signed informed consents and accepted to be involved in the study. In addition, approval from the Ethical Committee of ENT Department, Benha University, was obtained.

Patients were randomly allocated into four groups (A, B, C, and D) according to pack duration using sealed envelopes.

In group A, we removed the nasal pack 6 h after surgery, after 12 h in group B, after 24 h in group C, and after 48 h in group D.

Operative procedures

Patients underwent nasal surgeries including submucous resection (SMR) and/or inferior turbinoplasty or functional endoscopic sinus surgery (FESS). The surgical procedures were performed under general anesthesia by senior staff members.

SMR was carried out with resection of most of the deviated cartilaginous and bony septum with or without inferior turbinoplasty. Internal nasal splints were inserted into both nasal cavities and fixed by 3-0 Vicryl sutures.

Surgical procedures of inferior turbinate involved lateralization followed by resection of about half of the posterior part of the turbinate with the aid of an endoscope.

The extent of FESS varied according to the extent of disease and surgeon's individual practice, but usually classic FESS steps were followed.

At the end of all operations, the nose was packed with an antimicrobial, wet Vaseline dressing gauze, locally prepared in the hospital, and it was left in place for 6, 12, 24, and 48 h in groups A, B, C, and D, respectively.

Postoperative

Patients received systemic oral antibiotics, and pain medication if necessary. Alkaline nasal wash started one day after removal of the pack.

Follow-up visits

We scheduled evaluation of the patients in the presence of ANP, at the time of pack removal, weekly for the first month, and monthly for three months.

Pain during removal of the pack was evaluated with visual analog scale. Any epiphora, dysphagia, or sleep disorders before pack removal were evaluated.

Moreover, bleeding during pack removal was evaluated and how it was controlled (no bleeding, bleeding controlled spontaneously, bleeding controlled by ephedrine pack, or bleeding controlled by anterior Vaseline pack).

In addition, hematoma, postoperative infection, adhesions, and crustations after pack removal were evaluated (Fig. 1).

Data management and statistical analysis were done by using SPSS version 20, IBM Corp. Released 2011. IBM SPSS statistics for windows, version 20.0 Armonk, NY: IBM Corp.

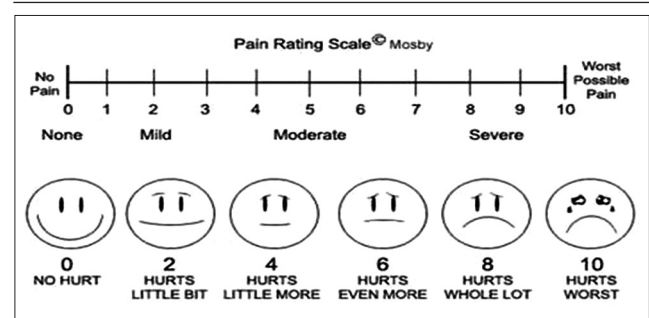
Descriptive statistics were calculated in the form of mean \pm SD for quantitative data and frequency and distribution for qualitative data.

In the statistical comparison between the different groups, the significance of difference was tested by using analysis of variance test (*P* value) to compare mean of more than two groups of quantitative data or Fisher's exact test for intergroup comparison of categorical data.

Results

A total of 150 patients were included in this study,

Figure 1



Visual linear analog scale (0–10 numeric pain distress scale) [5].

with a mean follow-up period of 3 months (range: 2–6 months).

Demographic criteria of patients are shown in Table 1.

ANP was removed after 6 h in group A, which included 37 patients; after 12 h in group B, which included 37 patients; after 24 h in group C, which included 38 patients; and after 48 h in group D, which included 38 patients.

Regarding the type of procedures performed in groups A and B, eight (21.6%) patients underwent submucosal resection of nasal septum (SMR), nine (24.3%) patients underwent turbinoplasty, 10 (27.03%) patients underwent SMR with turbinoplasty, and 10 (27.03%) patients underwent FESS.

Regarding the type of procedures performed in groups C and D, nine (23.7%) patients underwent submucosal resection of nasal septum (SMR), nine (23.7%) patients underwent inferior turbinoplasty, 10 (26.3%) patients underwent SMR with inferior turbinoplasty, and 10 (26.3%) patients underwent FESS.

Regarding the type of procedures performed in all groups, 34 (22.66%) patients underwent SMR, 36 (24%) patients underwent inferior turbinoplasty, 40 (26.66%) patients underwent SMR with inferior turbinoplasty, and 40 (26.66%) patients underwent FESS.

In all groups, mean pain score was significantly lower in group A and higher in group D regardless of the type of surgery (Tables 2-5).

Incidence of epiphora and sleep disturbances before pack removal was significantly lower in group A and higher in group D regardless of the type of surgery, whereas it was not significant regarding dysphagia (Table 6).

Complications

Group A

Four (10.8%) cases (two underwent turbinoplasty and two underwent SMR with turbinoplasty) had significant bleeding on pack removal that required anterior nasal repacking for 12–24 h.

The rest of the cases in the group showed no bleeding, minor self-limited oozing, or minor bleeding controlled by 1–3 ephedrine packs.

Single unilateral adhesion was noticed in four (10.8%) patients in group A: one after SMR with turbinoplasty,

Table 1 Demographic criteria of patients

	Group A	Group B	Group C	Group D	P
n	8	8	9	9	0.012*
Range	2-4	1-5	3-8	1-10	
MPS±SD	2.25±0.71	3.75±1.39	4.78±1.92	5.89±3.41	

MPS, mean pain score. *Significant.

Table 2 Mean pain score during pack removal in different study groups after submucosal resection operation

	Group A	Group B	Group C	Group D	P
n	9	9	9	9	0.006**
Range	1-5	1-7	2-9	3-10	
MPS±SD	2.67±1.32	3.33±1.8	3.78±2.17	6.22±2.77	

MPS, mean pain score. **Highly significant.

Table 3 Mean pain score during pack removal in different study groups after turbinoplasty operation

	Group A	Group B	Group C	Group D	P
n	10	10	10	10	<0.001**
Range	1-4	1-4	3-7	2-10	
MPS±SD	1.7±0.95	2.4±1.07	4.4±1.51	6.4±3.44	

MPS, mean pain score. **Highly significant.

Table 4 Mean pain score during pack removal in different study groups after submucosal resection with turbinoplasty

	Group A	Group B	Group C	Group D	P
n	10	10	10	10	<0.001**
Range	1-3	1-5	2-6	2-10	
MPS±SD	2.1±0.99	2.9±1.29	3.7±1.7	6.5±3.03	

MPS, mean pain score. **Highly significant.

one after FESS by the second week after pack removal, one after turbinoplasty, and the last one after FESS by the third week after pack removal. We cut the adhesion under local anesthesia with changing light Vaseline packs daily for a week.

There was only one case of small anterior septal perforation (2.7%) (underwent SMR with turbinoplasty) that started after 1 week of pack removal. It was asymptomatic.

Group B

Adhesions were noticed in four (10.8%) cases: one case (underwent FESS) 2 weeks after pack removal and three cases (two underwent SMR with turbinoplasty and one underwent FESS) 3 weeks after pack removal.

It managed as mentioned before.

Group C

One (2.6%) case (underwent SMR with turbinoplasty) had significant bleeding on pack removal that required anterior nasal repacking for 24 h.

Group D: it showed no bleedings, adhesions, or perforations.

Table 5 Mean pain score during pack removal in different study groups after functional endoscopic sinus surgery operation

	Group A [n (%)]	Group B [n (%)]	Group C [n (%)]	Group D [n (%)]	P
Epiphora	24 (64.9)	26 (70.2)	35 (92.1)	36 (94.7)	<0.001**
Dysphagia	26 (70.2)	26 (70.2)	31 (81.6)	33 (86.8)	<0.22
Sleep disturbances	7 (18.9)	12 (32.4)	22 (57.9)	25 (65.8)	<0.001**

**Highly significant.

Table 6 Epiphora, dysphagia, and sleep disturbances before pack removal in different study groups

	Group A [n (%)]	Group B [n (%)]	Group C [n (%)]	Group D [n (%)]	P	Time of notification
Bleeding+++	4 (10.8)	0	1 (2.6)	0	0.15	During pack removal
Adhesions	4 (10.8)	4 (10.8)	0	0	0.18	Second and third week
Perforations	1 (2.7)	0	0	0	0.80	First week
Crustations	16 (43.2)	17 (45.9)	19 (50.0)	21 (55.3)	0.74	Within first month
Infections	9 (24.3)	9 (24.3)	11 (28.9)	11 (28.9)	0.94	Within first month
Smell disorders	8 (21.6)	7 (18.9)	9 (23.7)	8 (21.1)	0.97	Within first month

Nonsignificant. Bleeding+++ : number of cases in which bleeding controlled by repacking by anterior nasal Vaseline pack

Table 7 Complications in the study groups and its significance

	n (%)
Sex	
Males	76 (50.7)
Females	74 (49.3)
Age	
Mean±SD	26.73±7.62
Range	18-50

All groups showed no significant difference regarding incidence of complications after ANP removal (Table 7).

Discussion

Nasal packing is used primarily to control bleeding in endonasal surgeries. It is also used to guard against some complications like hematoma and abscess formation. Removal of the nasal pack is considered as a bad memory and a horrible event in a large percentage of patients undergoing nasal surgeries. There are no generally accepted standards regarding how long the packing should be left in place [3]. In this study, we tried to reach the best duration for the pack after common nasal surgeries with the least discomfort, pain, and complications.

We included patients who underwent commonest nose surgeries in our community: SMR, turbinoplasty, and FESS. We used Vaseline packs, as it is the most widely used in our community. Other materials may have different results, which should be kept in mind.

Mean pain score was significantly lower in group A (6 h packing) and higher in group D (48 h packing) regardless of the type of surgery. Pain increased at the time of pack removal with longer pack duration. This may be attributed to dryness of the pack with

absorption of Vaseline or melting by body temperature and swallowing. It may be also owing to some sort of secondary bacterial infections and growths on retained blood and secretions. It needs no statistics to conclude that patient discomfort is direct proportionate with pack duration; the new point is that pain increases too at the time of its removal.

The incidence of epiphora and sleep disturbances before pack removal was significantly lower in group A, whereas the incidence of dysphagia and bleeding, adhesions, crustations, infections, and smell disorders after pack removal was not associated with significant difference in all groups.

These results coincide with Al-Arfaj *et al.* [6] who demonstrated that nasal packing for 6 and 24 h in patients undergoing septorhinoplasty showed no significant differences in the complications, whereas reduced patient discomfort and pain significantly. Results also agree with Thomas *et al.* [7] who concluded that postoperative nasal packing for only 2 h, in comparison with 24 h significantly, reduced pain without a concomitant risk of hemorrhage.

Gyawali *et al.* [8] reported nonsignificant postoperative bleeding, no postoperative septal hematoma, and less postoperative discomfort when the packs were removed early (after 2 h) and concluded that there was no significant difference in the postoperative events and recovery between removals of ANP after 48 h and after 2 h of operation.

Other studies refuse long pack period. Hajjioannou *et al.* [9] stated that one-day nasal dressing is preferable to that of two or more days because of less patient discomfort and increased cost-effectiveness without increasing immediate complications. Lubianca-Neto *et al.* [10] concluded that routine use of 48-h postoperative nasal packing after nasal surgery is not

justified for all patients. Sirimanna *et al.* [11] reported significant differences in postoperative complications between patients with 24 or 48-h postoperative nasal packing, and the number of complications was higher in patients packed for 48 h.

Some authors deny any significance of postoperative nasal packing such as Alimaheed and Alshehri [12] who concluded that packing should be reserved only for those who have bleeding tendency. Gioacchini *et al.* [13] concluded that nasal packing does not appear to be warranted as it seems to increase the number of complications without guaranteeing any important advantages. Kaygusuz *et al.* [14] reported that in comparison of postoperative nasal purulent discharge, there was no significant statistical difference between packing and nonpacking group.

Alimaheed and Alshehri [12] reported that patients who underwent nasal packing experienced significantly more epiphora, headache, and sleep disturbances. This agrees with our results.

It seems that there is not a single factor that determines the necessity of packing, and it should be chosen judiciously after observation of the bleeding status of the operation site with consideration of multiple relevant factors and it might not be considered as a routine step at the end of nasal surgeries.

On the contrary, some authors insist on the value of ANP. Wee *et al.* [15] demonstrated that nasal packing is necessary, and a packing material has benefits in both cost and efficacy.

Conclusions and recommendations

Nasal packing for 6 h after common nasal operations was associated with less discomfort before pack removal, less pain on pack removal, and was not associated with significant postoperative complications.

We recommend more studies comparing 6 h packing with less durations and with no packing. In addition, we recommend doing these studies on larger scales and

longer periods of follow-up. In addition, we recommend testing these factors in other nasal surgeries. In addition, we recommend comparing different pack materials results.

Financial support and sponsorship

Nil.

Conflicts of interest

There are no conflicts of interest.

References

- 1 Aksoy E, Serin GM, Polat Y, Kaytaz A. Removing intranasal splints after septal surgery. *J Craniofac Surg* 2011; 22:3.
- 2 Khayat FJ, Yaseen A, Amy SK, Joseph KH, Caniello M, Passerotti GH, *et al.* The effect of intranasal splint on prevention of adhesion after septoplasty. *Diyala J Med* 2012; 2:5-12.
- 3 Ardehali MM, Bastaninejad S. Use of nasal packs and intranasal septal splints following septoplasty. *Int J Oral Maxillofac Surg* 2009; 38:1022-1024.
- 4 Weber R, Keerl R, Hochapfel F, Draf W, Toffel PH. Packing in endonasal surgery. *Am J Otolaryngol* 2001; 22:306-320.
- 5 Zirak N, Esfahanizadeh J, Tashnizi MA, Sepehri Shamloo A, Motahedi B, Soltani G. Renal function following on-pump versus off-pump CABG. *Iran Heart J* 2014; 14:43-46.
- 6 Al-Arfaj A, Al-Swiahb JN, Al-Harthy S, Al-Essa M. Nasal packing in cosmetic and functional nasal surgery. *Saudi Med J* 2008; 29:994-997.
- 7 Thomas DM, Tierney PA, Samuel D, Patel KS. Audit of pain after nasal surgery. *Ann R Coll Surg Engl* 1996; 78:380.
- 8 Gyawali KR, Pokharel M, Amatya RC. Short duration anterior nasal packing after submucosal resection of nasal septum. *Kathmandu Univ Med J (KUMJ)* 2008; 6:173-175.
- 9 Hajioannou JK, Bizaki A, Fragiadakis G, Bouroulias C, Spanakis I, Chlouverakis G, *et al.* Optimal time for nasal packing removal after septoplasty. A comparative study. *Rhinology* 2007; 45:68.
- 10 Lubianca-Neto JF, Sant'anna GD, Mauri M, Arrarte JL, Brinckmann CA. Evaluation of time of nasal packing after nasal surgery: a randomized trial. *Otolaryngol Head Neck Surg* 2000; 122:899-901.
- 11 Sirimanna KS, Todd GB, Madden GJ. Early complications of packing after nasal surgery with three different materials. *Ceylon Med J* 1994; 39:129-131.
- 12 Alimaheed S, Alshehri MD. Assessment of complications of nasal packing after septoplasty. *Med J Cairo Univ* 2011; 79:2.
- 13 Gioacchini FM, Alicandri-Ciuffelli M, Kaleci S, Magliulo G, Re M. The role of antibiotic therapy and nasal packing in septoplasty. *Eur Arch Otorhinolaryngol* 2014; 271:879-886.
- 14 Kaygusuz I, Kizirgil A, Karlidağ T, Yalçın S, Keles E, Yakupoğullari Y, Alpay C. Bacteriemia in septoplasty and septorhinoplasty surgery. *Rhinology* 2003; 41:76-79.
- 15 Wee JH, Lee CH, Rhee CS, Kim JW. Comparison between Gelfoam packing and no packing after endoscopic sinus surgery in the same patients. *Eur Arch Otorhinolaryngol* 2012; 269:897-903.